

Rectovaginal Fistula in a Newly Married Woman

Demisew Amenu*

Obstetrician and Gynecologist, College of Public health and Medical Sciences, Jimma University, Ethiopia

*Corresponding author: Demisew Amenu, Obstetrician and Gynecologist, College of Public health and Medical Sciences, Jimma University, Ethiopia, Tel: +251 911 811468; E-mail: demisame5@gmail.com

Received date: Apr 30, 2015; Accepted date: Jun 01, 2015; Published date: Jun 08, 2015

Copyright: © 2015 Demisew A. This is an open-access article distributed under the terms of the Creative Commons Attribution License, which permits unrestricted use, distribution, and reproduction in any medium, provided the original author and source are credited.

Abstract

Rectovaginal fistula causes distressing symptoms and usually caused by obstetric trauma in developing countries especially in Sub Saharan Africa. The index case is reported to highlight the rare situation, where a 20 years old newly married woman developed low rectovaginal fistula following her first time coitus.

Keywords: Rectovaginal fistula; Postcoital

Introduction

A rectovaginal fistula is an epithelial communication between the rectum and the vagina. Rectovaginal fistulas may cause distressing symptoms, and their severity depends on the size and site of the fistulous tract [1]. Although coitus is a physiologic phenomenon, it may sometimes be risky especially in woman with little or no foreplay. Rectovaginal fistula (RVF) commonly occurs from obstetric injury. In developing countries; it is from child birth injury following obstructed labor in 76 to 97% and the rest can be from surgeries, malignancies and infections. Rectovaginal fistula following coitus usually arises from nonconsensual sexual intercourse in cases of sexual assault [2]. Consensual vaginal intercourse may lead to minor hymenal or vaginal tears sustained during vaginal penetration for the first time. However, rectovaginal fistula from consensual sexual intercourse is a rare event [3,4,8]. Very few case reports showed that postcoital rectovaginal fistula occurs proximal to the hymenal ring [5,6] or injury may involve the external anal sphincter [7]. Risk factors for genital injury following sexual intercourse include intercourse during pregnancy, puerperium, after gynecologic surgery, sexual assault and at menopause [8].

Case

A 20 years old, woman from a rural area presented in Jimma University Specialized Hospital, for a 3 day leakage of feces and of pervaginal flatus. It was the first night on her traditional wedding ceremony that she had her first time sexual intercourse with her husband. During intercourse, she had severe dyspareunia which was followed by bleeding; otherwise she didn't have leakage of feces or flatus the first three days after the event. The woman reported that there was no attempt of intercourse then after because of the bleeding and discharge, otherwise she perceived that this is a normal event which will happen to anybody during first intercourse.

After the third day she experienced offensive discharge from the injury site and shortly after, started to leak flatus and feces. For this problem she was brought to a private clinic by her husband and referred to the Hospital for repair. Her Gynecology evaluation revealed, stable vital signs, offensive discharge mixed with feces from the vagina coming out just between the posterior hymenal ring and perineal body (Figure 1). The hymen was torn only at 6 o'clock

position. After the site was cleansed, there was a recto-vaginal fistula (RVF) measuring 2 by 3 centimeters with infected necrotic edges, no involvement of the anal sphincters and perineum. Her laboratory investigations were within normal limit. With the diagnosis of low rectovaginal fistula from coital trauma, she was admitted to Gynecology ward and she was put on Broad spectrum antibiotics, the necrotic edge of the fistula was debrided and put on perineal care twice a day.

After two weeks stay in the hospital, she was evaluated and found to be fit for surgery. Patient was put on flood diet for 24 hours followed by an overnight fasting for 8 hours. Circumscribing incision made around fistula edge, vaginal mucosa mobilized from the rectum, fistula edge trimmed and closed in two layers with vicryl # 2-0 (Figure 2). Postoperatively the patient was continent to feces and flatus and discharged on sixth postoperative day with appointment. When client came Six weeks later for evaluation, the fistula healed and she was continent to both feces and flatus. The couple had already started sexual intercourse after the fourth postoperative week and reported no discomfort.

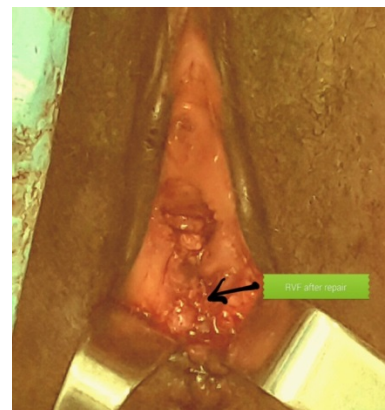


Figure2: RVF after repair.

Discussion

Rectovaginal fistula is a devastating condition; mainly from child birth injury following obstructed labor in developing countries where access to comprehensive obstetric care is limited [1]. Rectovaginal fistula from coital injury is reported in the case of sexual violence where excessive force will be used to control the survivor [2]. There are few case reports of rectovaginal fistula following consensual sexual intercourse [3,4, 7-9]. However; rectovaginal fistula during honey moon is a very rare event. It usually occurs on the lower one third of the rectum but proximal to the hymenal ring. The peculiarity in this case is that the fistula was found between the hymenal ring and perineal body which makes it different from the previous case reports published (Figure 1).

Even though small RVF may close without repair, it takes time and prolongs the woman's physical and psychological suffering and also may result in divorce. Therefore, early repair after treatment as in our case is essential to avoid related complications.

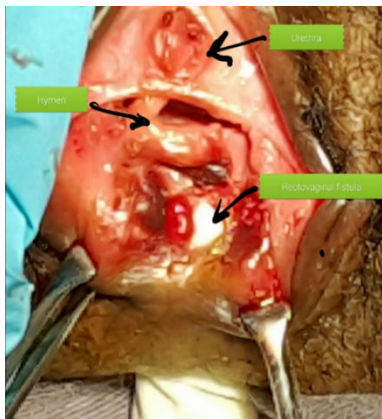


Figure 1: RVF before repair.

Conclusion

Early repair of postcoital RVF occurring during honeymoon has to be strongly considered based on the site and condition of RVF to hasten psychological recovery of couples and post repair counseling to avoid recurrence is essential.

Acknowledgment

I would like to thank the patient for allowing me to gather the necessary information.

References

1. Meeks G, Ghafar M (2012) Rectovaginal fistula. *Glob. Libr. Women's med.*
2. Onsrud M, Sjøveian S, Luhiriri R, Mukwege D (2008) Sexual violence-related fistulas in the Democratic Republic of Congo. *Int J Gynaecol Obstet* 103: 265-269.
3. Singh, Nisha (2013) Case Series of Three Postcoital Rectovaginal Fistulae. *J gynecol surg* 29: 70.
4. Abdullahi HM, Yakasai IA (2014) Coital laceration resulting in rectovaginal fistula: A case report. *Int J Curr Microbiol App Sci* 3: 845-849.
5. Uğurel V, Özer DP, Varol F (2014) A rare case of rectovaginal fistula following consensual vaginal intercourse. *J Sex Med* 11: 1345-1348.
6. Mitra P, Mukherjee S, Hassan H, soreng PS, Adhikari s, et al. (2012) Rectovaginal Fistula of Different Etiologies: Clinical Case reports. *NJOG* 7: 43-46.
7. Nupur Hooja, Premlata Mital, Nandaram Seervi, Hemlata Choudhary, Andaleeb Fatima, et al. (2013) Rectovaginal Fistula: A Case Report. *J App Med Sci* 1: 468-469
8. S Hembah-Hilekaan, I Pam (2010) Coitally Related Vagina Injury In A Woman In North Central Nigeria. *The Internet Journal of Sexual Medicine* 2.
9. Symeonidis N, Ballas K, Micha A, Psarras K, Pavlidis T (2015) Consensual intercourse resulting in an extensive rectovaginal tear: an extremely rare occurrence. *J Sex Med* 12: 572-575.