

Cerebral Coenurosis in Small Ruminants: A Review

Abera S., Wubit T. and Nejash A.

J Anim Sci Adv 2016, 6(3): 1595-1608

DOI: 10.5455/jasa.20160409121545



Cerebral Coenurosis in Small Ruminants: A Review

*Abera S., Wubit T. and Nejash A.

* Jimma University, College of Agriculture and Veterinary, Medicine, School of Veterinary Medicine, Jimma, Ethiopia.

Abstract

Cerebral coenurosis is an important disease affecting sheep and goat which causes significant economic losses in their production. Cerebral Coenurosis is caused by larval stage of *taenia multiceps* known as *coenurus cerebralis*. The aim of this paper is to review the general aspects of cerebral coenurosis in small ruminants' and highlight its economic and public health significance. Coenurosis occurs in worldwide and it is endemic in Ethiopia, especially in the highland area where sheep population is high. The life cycle is commonly happens between dog and small ruminants. The adult stage of this parasite inhabits the small intestine of dogs, foxes, coyotes and jackals; while larvae are found in the brain and spinal cord of intermediate hosts. When dog consume the brain containing coenurus cyst, cyst develop into *taenia multiceps* and then start to pass proglottid containing egg on pasture and intermediate hosts get infected when ingest eggs from pasture. Circling, Dullness, torticollis, loss of appetite, frequent bleating, separation from the flock, visual impairment, muscle tremors are the main clinical signs related with coenurosis. Diagnosis is mostly by necrosy while radiology, ultrasonography and CT can also be used. Treatment of choice is by surgical removal of the cyst or by aspiration of fluid from the cyst; also combination of Fenbendazole, praziquantel and albendazole is effective against migratory stage of the larvae. The disease causes great economic loss in small ruminant production. Human get infected with coenurosis if ingests an egg of the parasite accidentally. Regular anthelmintic treatment of dogs, correct disposal of sheep and goat brain are the main control method of coenurosis. The community should Control dog contact with pasture and have to properly dispose the brain of infected sheep and goats after slaughter; also they should keep their hygiene to prevent ingestion of *T. multiceps* eggs.

Keywords: Coenurus cerebrallis, tinea multiceps, coenurosis, small ruminants.

*Corresponding author: Jimma University, College of Agriculture and Veterinary, Medicine, School of Veterinary Medicine, Jimma, Ethiopia.

Received on: 23 Feb 2016

Revised on: 04 Mar 2016

Accepted on: 20 Mar 2016

Online Published on: 30 Mar 2016

1595 J. Anim. Sci. Adv., 2016, 6(3): 1595-1608

Introduction

Small ruminants are important domestic animals in the animal production systems of the world (Rosen *et al.*, 2005). Especially within the African society sheep and goat comprise a greater proportion of the total wealth of poor families because of low input requirements such as small initial capital, fewer resources and maintenance cost, ability to produce milk and meat using marginal lands and poor pasture and due to they need only short periods to reconstitute flocks after disaster and respond quickly to the demand (Dejene *et al.*, 2013).

While their extensive use, the productivity of small ruminants is mainly constrained by diseases, poor nutrition, poor management and poor breeding policies. Helminth parasite is the main diseases that affect sheep and goat productivity in the world (Gadahi *et al.*, 2009). Among helminth parasites larvae of *Tinea multiceps* known as *coenurus cerebralis* is the major disease affecting sheep and goat production and causes disease known as cerebral coenurosis in these animals (Sabbatani *et al.*, 2004).

Coenurus cerebralis, is the metacestode or larval form of the dog tapeworm *Taenia multiceps*, causes cerebral coenurosis, also known as gid or stagger (Oryan *et al.*, 2015). *C. cerebralis* causes a serious problem in sheep production (Scala *et al.*, 2007). The larval stage (metacestode) of this cestode, known as *C. cerebralis*, affects the CNS, particularly the brain of sheep and gives rise to the neurological signs of coenurosis (gid or stagger) (Tavassoli *et al.*, 2012).

Domestic and wild canids constitute the definitive hosts, while a wide range of herbivores including sheep, goats, cattle, buffaloes, camels, yak and equines are the intermediate hosts. Coenurosis is quite the commonly occurring disease in sheep compared to the other animals (Acha & Szyfres, 2003; Sharma and Chauhan, 2006). Dog being definitive host of *Taenia multiceps* plays an important role in spreading the disease (Alemu *et al.*, 2015). Dogs fed on the heads containing cerebral coenuri develops adult tapeworm in the duodenum and jejunum and the life cycle is

completed approximately 42-60 days after ingesting the *Coenurus* cysts (Oryan *et al.*, 2014).

Clinical sign is based on location and size of the *Coenurus* cyst in the brain and spinal cord (Avcioglu *et al.*, 2012). The resulting neurological signs in affected animals are gid or circling, ataxia, head deviation and blindness. Cerebral coenurosis is worldwide in distribution but most common in developing countries of Africa and south eastern Asia region and it is an endemic disease in Ethiopia (Acha & Szyfres, 2003; Moazami, 2005; Oge *et al.*, 2012; Adane *et al.*, 2015).

Necropsy finding of cyst, Clinical signs, CT, ultrasound and X-ray are the diagnostic method of coenurosis (Roy *et al.*, 2007). Histopathological findings revealed an extensive area of liquefactive necrosis in the cerebrum related to the evacuated *Coenurus* cyst also used as diagnostic method (Haridy *et al.*, 2013). Although the surgical removal of the cyst is the treatment of choice (Scott, 2012), mixture of anthelmintic agents (albendazole, praziquantel, fenbendazole) in treating coenurosis is successful in the early stage of infection (Ghazaei, 2007).

The infestation of animal with *coenurus cerebralis* lead to lower production and even death of the animals in cases of heavy infestations (Oryan *et al.*, 2012). It causes great economic losses in sheep and goat production by killing the animals or reducing the productivity of the animal or by condemnation of the organs (Sharma and chauhan, 2006; Rostami *et al.*, 2013).

The major economic losses associated to coenurosis of small ruminants for the export are abattoir brain condemnation, time and loss of energy to dissect the brain of small ruminants for export purpose (Adane *et al.*, 2015). Few human cases have been reported from different countries including Italy, Egypt and the United States due to coenurosis (Rostami *et al.*, 2013). Human beings can be infected with this disease if accidentally ingest the egg of this parasite (Acha & Szyfres, 2003). Therefore, the objective of this paper is to review the general aspects of cerebral coenurosis in small ruminants and to highlight its public health and economic significance.

Literature Review

Etiology

Cerebral Coenurosis (gid or sturdy) is caused by *Coenurus cerebralis* cyst, which is a metacestode or larval stage of *Taenia multiceps* and particularly affects sheep and goats (Sharma and Chauhan, 2006; varcasia *et al.*, 2012; Miran, 2013). The cysts are morphologically large, white, round or oval, have translucent structures and numerous protoscolexes attached to the wall and scolex has a double ring of rostellar hooks (Desouky *et al.*, 2011; Avcioglu *et al.*, 2012; Miran, 2013). The average number of scolexes in the metacestode is 85 with a range of 40-550 scolexes per coenuri (Rostami *et al.*, 2013). Cysts are approximately 0.8-6.5cm in diameter and are filled with large amount of fluid. In addition, they contain numerous macroscopic invaginated scolices. Microscopically the scolices shows the C-shaped suckers and a rostellum armed with typical taenia hooks arranged in double rows (Neni, 2012; Oge *et al.*, 2012).

The length of the adult *T. multiceps* is up to 100 cm. The scolex has four cup shaped suckers and bears a rostellum which has two rows of hooks. The number of hooks in each scolex is variable, ranging from 22 to 32. The length of the large hooks recorded from 180 to 198 μm and the length of the small hooks ranges 108 to 126 μm (Oryan *et al.*, 2014). The eggs of *taenia multiceps* are 29 to 37micrometer in diameter and contain single oncosphere with three pairs of hooks (Mandal, 2005). *Taenia multiceps* of adult parasite matured in and inhabit the small intestine of dogs, foxes, coyotes and jackals or mostly the small intestine of canids (Miran, 2013). The cystic larvae are mainly found in the brain and in some instances in the spinal cord of small ruminants and resulting in neurological signs, such as gid, ataxia, head deviation and blindness (Oryan *et al.*, 2014). Such neurological signs, in the majority of cases, result in

the death of the affected animals (Avcioglu *et al.*, 2012). In humans, these larvae are usually found in the brain and cause neurocoenurosis (Scala *et al.*, 2007).

Life Cycle

The life cycle is indirect with sheep and goats acting as an intermediate host. Coenuruses results from ingestion of contaminated pasture with eggs. After ingestion of the eggs, the gastric and intestinal juices digest the embryo and the onchosphere is activated. After penetrating the gastric and intestinal mucosa, it passes into the blood and lymphatic circulation. Only those which reach the CNS develop to form metacestodes in 2-8 months and induce nervous symptoms and death. The rest, which reach other tissues, will die. The onchosphere of *Taenia multiceps* has a specific affinity for nervous tissue and eventually lodges in two predilection sites (Brain or spinal cord). This is due to the CSF is required for the differentiation, nourishment and growth of the metacestode and the scolices develop from the base of the invaginated outer surface of the metacestode wall (El-Din, 2010).

In the small intestine of the final host, *Taenia multiceps* reach maturity after 40-42 days. After the prepatent period, the dog starts to disseminate daily 3-4 proglottids, which contain approximately 37,000 eggs each. *T. multiceps* eggs are usually released from the proglottids before they are voided in the faeces. Eggs contaminate the environment and waters and resist for 15 days under dry conditions, or 30 days with high level of humidity. At high temperatures, they died in a few hours. When ingested by ruminants, in the small intestine the oncospheres spread from eggs and through the blood circulation they reach various locations, but only in the CNS they could develop into mature Coenurus cysts (Scala and Varcasia, 2006).

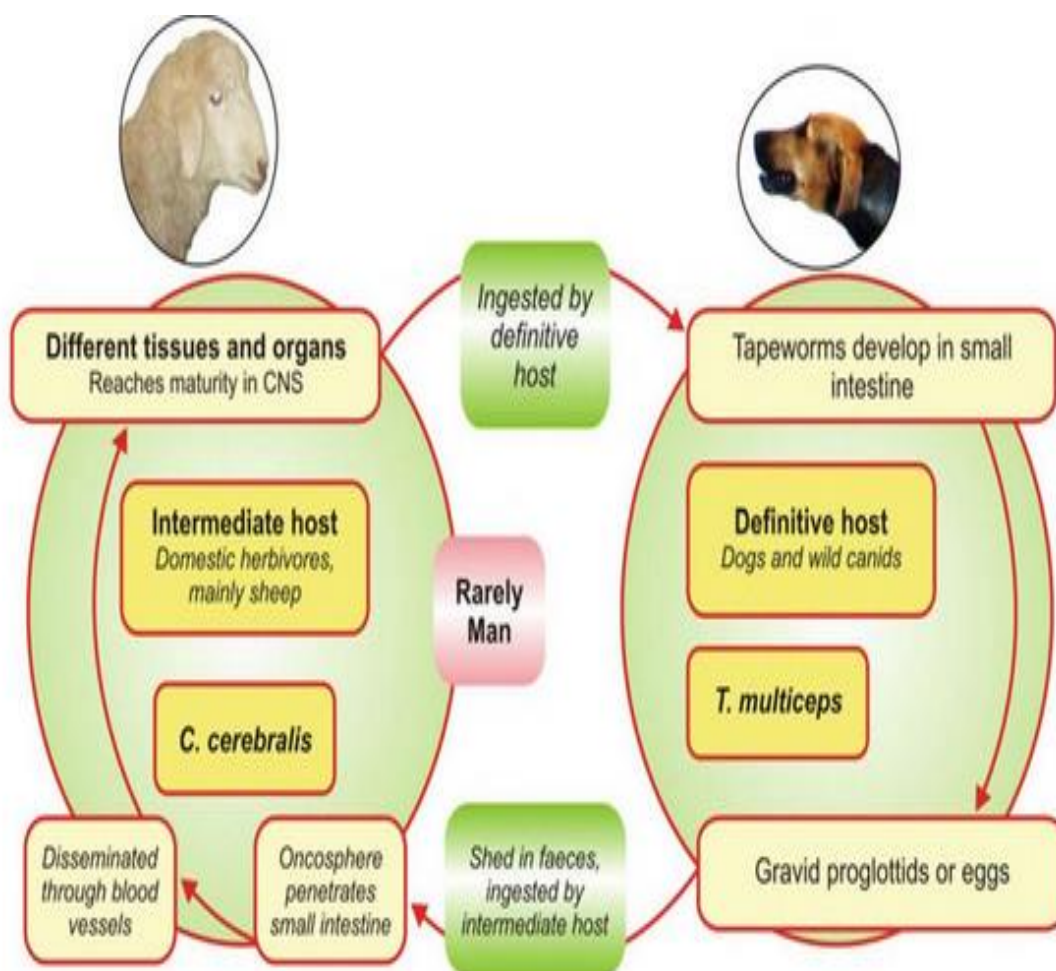


Fig. 1: coenurus cerebralis life cycle involving intermediate and definite host

Source: (Dhaliwal and Julal, 2013).

The *Coenurus cerebralis* has unusual power of asexual division giving rise to 400-500 of protoscolices invaginated from the inner cysts wall so that large number of scolices which appear as white clusters are attached to the internal layer of the wall of the superficial cyst (Nourani & Pilari Kheirabadi, 2009; Oryan *et al.*, 2014). The cyst takes approximately eight months to mature, during which it becomes progressively larger, as the volume of the fluid increases. At maturity, it can reach a diameter of five centimeter or more in which it will result in the onset of clinical signs due to increased intracranial pressure causes deviation of the head, headache, stumbling and paralysis. Again when this mature cyst is eaten by definitive host scolex exvaginates and attached to small intestinal wall of definitive host turn in to adult parasite and the cycle continues (Adane *et al.*, 2015).

Epidemiology

Geographic Distribution

Infection by the larval stage of the tapeworm *T. multiceps* in small ruminants is common in worldwide (Oryan *et al.*, 2014). It has been documented in scattered foci throughout the world, including the Americas and parts of Europe and is distributed in the worldwide (Abo-Shehada *et al.*, 2002; Sharma and Chauhan, 2006). In Africa, the disease (coenurosis) has been documented in Ethiopia, Ghana, Mozambique, Uganda, Egypt, Democratic Republic of Congo, Senegal, Sudan, Chad, Angola, Kenya and Southern Africa (Miran, 2013). It has been reported that 2.9% sheep in Jordan (Abo-Shehada *et al.*, 2002), 18.65 % in Uramia abattoir, Iran (Tavassoli *et al.*, 2011), 14.8 % in Tete municipal abattoir, Mozambique (Afonso *et al.*, 2011), 44.4 % Ngorongoro district, Tanzania

(Miran *et al.*, 2015), and 3.1–28.5% in Kars Province of Turkey (Gicik *et al.*, 2007; Uslu & Guclu, 2007) have been infected with the cerebral form of the *C. cerebralis*. There are many reports regarding the cerebral form of the coenurosis in Europe, including Greece (Christodouloupoulos, 2007; Christodouloupoulos *et al.*, 2008). The disease also has been reported in sheep, almost in all 31 provinces of Iran. Prevalence of 18.65% in West Azarbaijan Province, northwestern Iran (Tavassoli *et al.*, 2011), 0.007% in Kerman province eastern Iran (Kheirandish *et al.*, 2012).

Transmission

The transmission cycle of infection by *T. multiceps* takes place between dogs and domestic herbivores (Guclu *et al.*, 2006). The main factor in maintaining the parasitosis in nature is access by dogs to the brains of dead or slaughtered domestic herbivores that were infected with coenuri. *Taenia* eggs expelled in the feces of infected dogs or other canids are the source of infection for man and for the other intermediate hosts. In general, the eggs are eliminated by the definitive host in the proglottids. Since these dry out rapidly and are destroyed outside the host, the eggs are released and dispersed by the wind, rain, irrigation, and waterways and ingested from pasture by herbivores animals (Acha & Szyfres, 2003).

Dogs are routinely fed on offal, including sheep and goats head. After eating the brain containing the *C. cerebralis*; the *T. multiceps* develop within the intestine of dog and start to pass proglottid which again contaminate the pasture. Human can be intermediate host if eggs are accidentally ingested as result of poor personal hygiene after being shed in the faces of the dog (Lescano & Zunt, 2013; Adane *et al.*, 2015).

Host Range

Domestic and wild canids such as dog, fox, wolf and jakals constitute the definitive hosts; while dog is the most common definitive host for this parasite due to more exposure to the brain of sheep and goat. Wide range of herbivores including sheep, goats, cattle, buffaloes, camels, yak and equines are the intermediate hosts. Coenurus is quite common in sheep and goat compared to the other animals.

Human can get infected with this parasite if accidentally ingest the egg of the parasite (Sharma and Chauhan, 2006; Lescano and Zunt, 2013; Oryan *et al.*, 2015).

Risk Factor

The presence of shepherd (dog used as sheep keeper) dogs on grazing land as well as in paddocks, greatly contributes to the existence of the disease. Dogs are frequently fed on viscera, trimmings, and heads of butchered animals, and they are not treated for parasitic diseases, thus maintaining *C. cerebralis* – *T. multiceps* life cycle. Introduction of dog or sheep with *taeniamulticeps* or *coenurus cerebralis* in to an area where the disease is less prevalent, could pose a considerable risk for the introduction of coenurus into the new area (Gicik *et al.*, 2007; Jibat *et al.*, 2008).

Farmer or the owner often facilitate the contamination of the environment by opening the skull of infected sheep leaving the *Coenurus* cyst free to be eaten by dogs or, feeding them directly with the definitive host (Scala and Varcasia, 2006). The higher percentages of ecological variables (rainfall, relative humidity and air temperature) are considered to be the influencing factors for coenurosis. In rainy season, rain causes spread of feces of dog, fox (Final host) over the grasses and these contaminates are responsible for the increased occurrence of gid during rainy season (Hashim *et al.*, 2000). According to Gicik *et al.*, (2007) selling of sick animals to abattoirs or market by owners as soon as they noticed the coenurosis without informing the local authorities leads to the high prevalence of *Coenurus cerebralis* in the area.

Pathogenesis

The cerebral form of the coenurosis is referred to as either acute or chronic gid or sturdy; while the chronic form is more common than acute one (Alemu *et al.*, 2015). Acute coenurosis occurs as the result of larval migration in the central nervous system when several viable eggs are ingested by an herbivore animal (Oryan *et al.*, 2014). Consequences of migration of larvae in the brain causes liquefactive necrosis associated with thin walled larvae and infiltration of inflammatory cells, hemorrhage and necrosis. Liquefactive necrosis

with mild to moderate infiltration of the inflammatory cells such as eosinophils, lymphocytes, macrophages and neutrophils seen in the cerebellar cortex (Kish *et al.*, 2015). The signs are associated with an inflammatory and allergic reaction (Giadinis *et al.*, 2012). Usually there is transient pyrexia, and relatively mild neurological signs such as listlessness and a slight head aversion. In rare cases the signs are more severe and the animal may develop encephalitis, convulse and die within 4-5 days (Miran, 2013). An acute meningoencephalitis may develop if a large number of immature stages migrate in the brain and young lambs/kids aged 6-8 weeks are most likely to show signs of acute disease (Özkan *et al.*, 2011).

Chronic coenurosis mostly occurs in older animals of more than 6 months age, where it presents as a consequence of cyst development and slowly create local lesion in the cerebrum, cerebellum and spinal cord. The pressure applied on the vital organ as the cyst is filled with fluid through the time also play great role in development of the clinical signs. However, it typically involves one cerebral hemisphere and to a lesser extent the cerebellum (Oryan *et al.*, 2014).

Clinical Manifestation

Clinical syndrome is based on location and size of the *Coenurus* cyst in the brain or spinal cord (Avcioglu *et al.*, 2012). The time taken for the larvae to hatch, migrate and grow large enough to present nervous dysfunction varies from 2 to 6 months (Giadinis *et al.*, 2012).

Both acute and chronic forms of coenurosis can occur in animal, although chronic disease is more readily identified and more frequently reported (Scala and Varcasia, 2006). The clinical signs of acute form are correlated with the number of ingested eggs, the immune status of the host, the migrating route localization of parasites in the brain, and the intensity of inflammatory response (Alemu *et al.*, 2015). Death without prior symptoms has been reported from sheep with acute coenurosis (Ioannidou *et al.*, 2015). Acute coenurosis has been reported in a flock of sheep introduced in a pasture heavily contaminated by dog faeces (Giadinis *et al.*, 2012). Clinical signs appeared within 10 days, which ranged from mild to severe with death

occurring within 3–5 days after onset of neurological dysfunction. Acute coenurosis has also been reported in 6–8 week-old lambs, where clinical signs ranged from pyrexia, listlessness and head aversion to convulsions and death within 4–5 days. Chronic coenurosis is more commonly reported in growing sheep aged 6–18 months, where it presents as a slowly progressive focal lesion of the brain, typically involving one cerebral hemisphere. Chronic coenurosis has rarely been reported in sheep older than 3 years. The time taken from larval hatching, migration to the brain and evidence of neurological dysfunction varies between 2 and 6 months (Scott, 2012).

The main clinical signs in goats and sheep include dullness, circling, torticollis, loss of appetite, frequent bleating, separation from the flock, visual impairment, muscle tremors, pain response on pressure over the cystic area and sometimes unilateral partial blindness correlated cystic presence in cerebrum with depression, tilting of the head either towards right or left, head pressing, feet stamping or walking in straight line (Sharma and Chauhan, 2006; Gicik *et al.*, 2007).

Circling became obvious as the disease progressed, whereas head deviation observed during the early course of the disease. Cases with clockwise circling had at least one cyst in the right cerebrum. Similarly, cases of anticlockwise circling had at least one cyst in the left cerebrum. This indicates that coenurotic sheep tend to circle in the direction of the affected part of the brain. A few coenurotic sheep circled neither to the right nor to the left due to the involvement of the cerebellum and cerebral hemispheres. A coenurotic sheep carries or lowers its head to alleviate the pressure exerted by the cyst, depending on the location of the cyst in the brain, thus head position is low when the hind cerebrum is involved and high when the front cerebrum is affected. The predicted cyst locations based on the direction of circling and head deviation showed (Achenef *et al.*, 1999)

Systematic clinical examination of the animal demonstrated symptoms like inertia, in coordination, irregular gait, failure to hold the head straight, left ward head tilt and circling abnormal clinical sign is observed (Özkan *et al.*, 2011). When the metacestode localizes in spinal cord it results in

progressive paresis or hind legs paralysis (Oryan *et al.*, 2014). Young lambs/kids aged 6-8 weeks are most likely to show signs of acute disease and the signs are associated with an inflammatory and allergic reaction. There is transient pyrexia, and relatively mild neurological signs such as listlessness and a slight head aversion. Occasionally the signs are more severe and the animal may develop encephalitis, convulse and die within 4 - 5 days (Miran, 2013; Adane *et al.*, 2015).

Pathological Findings

After the head of the animal is dissected a cyst of 9x7 cm size over the caudal portion of the cerebral hemisphere or in the other parts of the brain. Owing to the drainage of the cystic fluid during removal of the brain, the cerebral tissue in this area is tend to collapse (Özkan *et al.*, 2011). During the acute phase of coenuruses, pale yellow tracts are visible on the surface of the brain, and in cut sections of brainstem and cerebellum. In chronic coenurosis, the increased intracranial pressure from the cyst compresses surrounding brain tissue and may result in softening of an area of the skull, but such changes may not occur in bone immediately overlying the cyst. Hydrocephalus may result from a coenurus cyst in a ventricle or the cerebral aqueduct. Increased intracranial pressure may cause herniation of the vermis of the cerebellum through the foramen magnum or the cerebrum may become herniated beneath the tentorium (Scott, 2012; Miran, 2013).

Coenuri in the brain caused damage to surrounding tissues, including thinning of the cerebral grey and white matter owing to focal pressure atrophy and liquefactive necrosis. The meninges are hyperaemic and oedematous, and microscopically there are degenerative and necrotic lesions in the brain. Within the brain, sections of coenuri of various shapes surrounded by marked eosinophilic necrotic tissues (Kheirandish *et al.*, 2012).

According to Ioannidou *et al.*, (2015) evaluation of the brain sections revealed foci of cavitations accompanied by compression of adjacent parenchyma (interpreted as malacic lesions by the migratory larvae). Each cavity was surrounded by cellular debris and numerous

macrophages, fewer lymphocytes and plasma cells and a peripheral rim of congested blood vessels. In one cavity the thick eosinophilic tegument of a cestode larva (Coenurus) was found. There were also multiple granulomas consisting of central dark eosinophilic amorphous material that was surrounded by multinucleated giant cells, degenerated and nondegenerated neutrophils, lymphocytes and plasma cells in the white matter, peri-vascular cuffs of lymphocytes and plasma cells, gliosis and formation of glial nodules were detected. Morphological diagnoses are pyogranulomatous meningoencephalitis, multifocal, severe with necrosis, compression and coenuri and lymphocytic perivascular cuffing.

Diagnosis

Diagnosis of cerebral coenurosis in the intermediate hosts can be made by recovery and examination of the cyst (Acha & Szyfres, 2003). The disease can be diagnosed on the basis of history, clinical signs and on the basis of the postmortem examinations in the animals died due to this disease (Uphadhayas, 2005). Diagnosis of the cerebral coenurosis is dependent on the clinical manifestations, neurological examination, ultrasound examination and post-mortem examination (Godara *et al.*, 2011; Biswas, 2013).

Animal cerebral coenurosis is usually diagnosed based on a clinical examination protocol and seldom includes imaging methods like radiology, ultrasonography and CT which are mainly used in experimental situations. Immunodiagnosis tests such as skin test for immediate hypersensitivity, indirect haemagglutination antibody test, immuno-electrophoresis, gelldouble diffusion, ELISA tests have been used experimentally. Despite the availability of these tests which have their own practical challenges, post mortem findings of a thin walled cyst filled with transparent fluid and with numerous scoleces in the wall remain the definitive diagnosis (Afonso *et al.*, 2011).

According to Miran *et al.*, (2013) post mortem examination for the diagnosis of coenuruses is as the following: The heads of slaughtered sheep and goats collected, followed by skin removal and careful opening of the skull using a machete or

other instrument without damaging the brain. Meninges incised using a scalpel blade to expose brain tissue. The whole brain of each individual animal collected and examined for visible evidence of cyst (*C. cerebralis*). The number and location of cysts seen (described as right hemisphere, left hemisphere or cerebellum) recorded.

Molecular characterization by PCR shows positive result for cerebral cysts in the naturally and experimentally infected sheep and goats, by producing the expected fragments for COX-1 and NAD1 genes. Sequence analysis showed that the sheep and goats samples examined in the naturally and experimentally infected samples are 100% identical to each other and 100% similar to adult worms recovered from dogs based on both mitochondrial markers (Oryan *et al.*, 2015).

Based on histopathological findings the affected cerebral hemisphere reveals multiple scolices growing on the internal layer of the cyst. Such developing cerebral cysts are accompanied with increased intracranial pressure and thinning the cerebral grey and white matter and in some instances the skull.

The cerebral tissues around the *Coenurus* cyst show neuronal degeneration, demyelination, necrosis, hyperemia, perivascular cuffing, diffuse astrocytosis and microgliosis leading to formation of microglial nodules and pressure atrophy in the skull. There is liquefactive necrosis around the cerebral cysts due to degenerative changes, with satellitosis, neuronophagia and diffuse gliosis. Numerous chronic abscesses with frequent calcification observed in the affected hemisphere of the brain. The wall is formed of a thick layer of fibrous tissue with numerous blood vessels surrounded by mononuclear lymphocytes and eosinophils (Haridy *et al.*, 2013). The meninges of the infected animals were hyperemic and edematous. No capsule of fibrous connective tissue enclosed the cerebral form of *Coenurus*. Examination of the H&E stained sections showed granulomatous encephalitis with caseation, encephalomalacia and Langhans giant cells. Necrosis and dissociation of ependymal cells with subventricular edema is consistent. Degeneration and necrosis of oligodendroglial cells noticed, in

addition to the axonal swelling and demyelinations (Oryan *et al.*, 2014; Ioannidou *et al.*, 2015).

Differential Diagnosis

Coenurus cerebralis may be found upon necropsy in the brain of sheep and goat but the condition needs to be differentiated from other local space occupying lesions of the cranial cavity and spinal cord including abscess and tumor. Hemorrhage in the early stage of the disease may be confused with encephalitis because of signs of brain irritation (Adane *et al.*, 2015).

Listeriosis, loupingill, scrapie and brain abscessation and tumor should be considered as the differential diagnosis of the cerebral coenurosis (Uphadhyay, 2005; Godara *et al.*, 2011). Scrapie would typically affect sheep older than three years; poliomyelomalacia causes diffuse bilateral cerebral signs, listeriosis results in multiple unilateral cranial nerve deficits, while focal symmetrical encephalomalacia results in rapid death. A thorough neurological examination should therefore permit an accurate diagnosis of *coenurosis* (Scott, 2012).

Listeriosis is an infection caused by the bacterium *Listeria monocytogenes*. The disease can affect sheep, goats and cattle. Symptoms include depression, decreased appetite, fever, stumbling or moving in one direction only, head pulled to flank with rigid neck, facial paralysis on one side, slack jaw, and abortions. The disease is curable by use of antibiotics such as procaine penicillin (Miran, 2013).

Scrapie is an infectious transmissible fatal degenerative disease affecting the central nervous system of sheep and goats. The disease is caused by a prion (protein particle similar to a virus but lacking nucleic acid) and is usually observed in animals older than 2 years. Early signs include subtle changes in behavior or temperament. These changes may be followed by scratching and rubbing against fixed objects, loss of coordination, weakness, weight loss despite retention of appetite, biting of feet and limbs, lip smacking, and gait abnormalities, (high-stepping of the forelegs, hopping like a rabbit, and swaying of the back end) and the disease is often accompanied by pruritus (Fentahun and Fresebehat, 2012; Miran, 2013).

Louping ill results from infection by louping ill virus, a member of the genus *Flavivirus* in the family Flaviviridae. This virus is closely related to tick borne encephalitis virus. The incubation period for louping ill is six to 18 days in sheep. Louping ill is characterized by an initial febrile viremic stage, which may be accompanied by depression and anorexia, followed in some cases by neurological signs. Affected sheep may develop an unusual hopping gait, called a “louping gait,” during which they move both hindlegs, then both forelegs, forward in unison. Death is common among animals with neurological signs, often within a few days. Peracute deaths can also be seen. Surviving animals may have residual CNS deficits. Louping ill should be suspected in sheep with fever and neurological signs, particularly when the flock has recently been introduced to tick-infested pastures. It should also be a consideration in grouse with a fatal illness (Balseiro *et al.*, 2012).

Zoonotic Importance of Cerebral Coenurosis

Coenurus cerebralis in human beings diagnosed for the first time in 1913 in Paris, when a man presented symptoms of CNS nerve degeneration. He had convulsions and trouble speaking/understanding speech. During his autopsy, two coenuri were found in his brain. Recently (within the last 25 years), human cases have been recorded in Uganda, Kenya, Ghana, South Africa, Rwanda, Nigeria, Italy, Israel, Mexico, Canada and the United States, and animal cases have been found in many other countries as well. In 1983, a 4-year-old girl in the USA was admitted to the hospital with progressive, generalized muscle weakness, inability to walk, rash, abdominal pain and deteriorating neurological ability. When the doctors did a CT scan, they saw fluid filled lumps in her brain and decided to operate. While operating, coenuri were found and the patient was immediately given chemotherapy with praziquantel. Unfortunately, the coenurosis had already done too much damage in the CNS and the little girl did not survive. In these cases, the infected individuals had been exposed to wild dogs in regions where canid tapeworm is considered endemic, and probably ingested the parasite accidentally through contact with contaminated food or water (Bechelli, 2005).

Coenuruses is a relatively rare zoonotic disease of humans, caused by the larval stage of a dog tape worm *Taenia (Multiceps) multiceps*. Human infection occurs if eggs are accidentally ingested as result of poor personal hygiene after being shed in the faces of the dog. After ingestion of the eggs, larvae hatch, penetrate the intestinal wall and migrate to various tissues, where they develop in to large, cystic larvae. Symptoms are secondary to the presence of a cyst in a vital structure. Patients with coenuruses present with headache and papille edema. The cysts have been responsible for epilepsy, hemiplegia, monoplegia and cerebral ataxia. When the spinal cord is affected there may be spastic paraplesia, lymphadenopathy, fever and malaise can occur, raising the suspicion of lymphoma (Adane *et al.*, 2015).

The cerebral form of coenurosis in human is the most serious one. Several years may pass between infection and the appearance of symptoms and the symptoms varies with the neuroanatomical localization of the coenurus: cerebral coenurosis is manifested by signs of intracranial hypertension, and the disease is very difficult to distinguish clinically from neuro cysticercosis or cerebral hydatidosis. Symptoms that may be observed consist of headache, vomiting, paraplegia, hemiplegia, aphasia, and epileptic form of seizures. Papilledema is a sign of increased intracranial pressure. The coenurus can also develop in the vitreous humor and may affect the retina and choroid. The degree of damage to vision depends on the size of the coenurus and the extent of the choroido retinal lesion. The prognosis for coenurosis of the nervous tissue is always serious and the only treatment is surgery, although recently, the testing of treatment with praziquantel or albendazole has begun (Acha & Szyfres, 2003). There are more than 100 reports of human infection with these metacestodes. The cerebral coenurosis create serious problems and even death in patients (Oryan *et al.*, 2015).

Humans are dead-end intermediate hosts and become infected by ingesting eggs passed in the excrement of a definitive host. The ingested eggs release oncospheres in the host intestine that penetrate the intestinal wall and migrate toward target organs through the blood stream, usually

lodging in the brain, spinal canal, or eye. In the brain, the coenurus causes inflammation (coenurosis) in the parenchyma, and its presence along the cerebrospinal fluid pathways eventually leads to basal arachnoiditis or ependymitis. The most common signs and symptoms of this condition are headache, seizures, vomiting, and papille edema (Haïtchi *et al.*, 2012; Lescano and Zunt, 2013).

Economic Importance of Cerebral Coenurosis

Cerebral coenurosis is an economically important disease as it causes serious problems especially in the sheep industry and breeding (Scala and Varcasia, 2006; Varcasia 2009; Kheirandish *et al.*, 2012). The disease has 100% mortality rate which cause severe economic losses in small ruminants (Upadhyay, 2005). Gicik *et al.*, (2007) reported that as coenurosis is one of the major contributors to sheep mortality, especially in young sheep of the region in Kars province in Turkey.

Miran (2013) show that Coenurosis ranked amongst the most important sheep and goat's diseases in Tanzania, where 58.8% and 47.9% of respondents ranked it as the disease of most concern in sheep and goats respectively in terms of mortality and all have felt the effects of the disease. Among the direct losses arising from cerebral coenurosis are emergency sales or slaughter of affected animals once the clinical disease became apparent and sometimes death occur.

In Ethiopia, according to Deressa *et al.*, (2012) total annual financial loss due to brain/animal condemnation estimated at 8330 Ethiopian Birr (490 US\$). Main causes of brain condemned is due to brain with a higher *coenures cerebralis* cyst. Though brain is not a common dish for Ethiopians, there is a higher demand in the Middle East countries (Jibat *et al.*, 2008).

One study done on coenurus cerbrallis in sheep and goat in and around Yabello district of Borena zone in Ethiopia shows that economic implication of coenurus presented with the direct losses due to death of sheep and goat and reduction in market prices due to aesthetic values. According to this study numbers of animas died due to coenorosis during 2011 were a total of 692 heads of sheep and goats with average heads of sheep and goats per respondents and 40 clinically diseased

animals from the total 399 examined animals during the five months of this study. The financial losses from mortality during the year 2011 estimated to be 363300ETB (20760US\$), whereas average losses from aesthetic value from 399 examined animals were about 11000ETB. On average farmer in Yabello lost 4725ETB (Neni, 2012).

Jawar (2015) also reported that the economic losses during the year 2014 in Lega Hida district was estimated to be 398,250ETB(19432.61US\$); whereas average losses from aesthetic value of 50 clinically diseased animals with indirect losses is about 69688.4ETB. The total economic losses due to coenuruses at Lega Hida district is 467938.4ETB.

Status of Cerebral Coenurosis in Ethiopia

According to Adane *et al.*, (2015) Coenurosis is an endemic disease in Ethiopia, especially in the highland sheep where 75% of the population is found. The presence of freely roaming dogs in grazing land greatly contributes to the existence of the disease. Dogs are routinely fed on offal, including sheep and goats head, and are not dewormed. Thus maintaining the *C. cerebralis-Taenia multiceps* cycle. According to their study 3.78% of sheep and goats slaughtered at Hashim Export Abattoir in Debre Zeit were found to be infected with *Coenurus cerebralis*.

Achenef *et al.*, (1999) carried out an investigation at Debre Berhan, Ethiopia between 1996 and 1997, in the epidemiology of coenurosis in Menz and Horro breeds of sheep. A total of 37 heads from clinically sick and 183 heads from apparently healthy sheep were examined postmortem for the presence of the cystic larvae of *Taenia multiceps*, of which 37 and 5 heads, respectively contained 1 to 8 coenurus cysts.

Deressa *et al.*, (2012) report that of a total 445 sheep heads examined, 21(4.7%) were found to be affected by coenuruses from sheep brain harvested at Ethiopian Health and Nutrition Research Institute of Ethiopia. Postmortem examination showed that *Coenurus cerebralis* occurred with a range of 1 to 5 cysts in each animal. One cyst occurred most frequently (61.9%) followed by 3, 4, and 5 cysts. The great majority of the cysts (94.4%) were located in the cerebral hemisphere where as 5.4% of cysts were localized on both sides of the middle

cerebellar hemisphere. Out of 21 infected brains, 15 (71.4 %) and 6 (28.6%) were trimmed and rejected, respectively. From the total of 6 rejected (total condemned) brain, all of the 6 (100.0%) brains had deep lesions.

According to Neni (2012) from 339 examined sheep and goats from different areas of yabello and surrounding areas for slaughtering. 46 of them were found to be infected with *coenurus cerebralis* in different part of the brain. Jawar (2015) also reported that from the total of 412 sheep and goats examined for *C. cerebrallis* in and around Lega Hida district of Bale zone, 52 of them were found with *coenurus cerebrallis* cyst in one or different parts of the brains.

Control and Prevention

Control of coenurosis in livestock relies on the same measures as those used to prevent other metacestodoses (Varcasia *et al.*, 2009). Cerebral coenurosis can be controlled by regular anthelmintic treatment of dogs at 6–8 week intervals, by using an effective taenicide, and correct disposal of sheep and goat brain after slaughtering or death of animals to prevent scavenging by dogs belonging to the general public, which may not receive regular anthelmintic treatment (Scott, 2012).

Effective control measures can also be taken by methods such as prohibition of backyard slaughtering, disposal of heads, and public awareness of the epidemiology of the *coenurus cerebralis* (Gicik *et al.*, 2007).

Communities and governments can make sure their water supply remains sanitary and free of dog feces. Communities can control number of stray dog populations. Individuals should wash all fruits and vegetables thoroughly before eating and make sure their dogs are not infected with tapeworm (Bechelli, 2005). For man, individual prevention from coenuruses consists of avoiding the ingestion of raw food or water that may be contaminated with dog feces (Acha & Szyfres, 2003).

Treatments

Treatment is by surgical removal of the cyst or by aspiration of the cyst fluid through the softened skull. This treatment is usually reserved for valuable animals, although the method described is fairly

straight. Indeed, the determination of the localization is the most problematic factor in the successful treatment of coenuruses (Upadhayay, 2005).

Treatment based on surgical removal of the coenurus cyst after general anaesthesia of the animal, achieves a very good success rate, especially after accurate anatomic localization of the lesion within the brain (Scott, 2012). Surgery of the skulls and brains of Sheep with cerebral coenurosis would be effective up to 90%, if the brain and skull are first tested by magnetic resource imaging or ultrasonography (Manunta *et al.*, 2012)

According to Ghazaei (2007) combination of fenbendazole together with praziquantel and albendazole is effective against the *cerebral coenurosis*. He has shown that praziquantel administration with dosage rates of 50 to 500 mg/kg resulted in successful treatment of this metacestode. Chemotherapy could be applied only in migration stages of the parasite. The efficacy of the antiparasitic drugs such as albendazole, fenbendazole, and praziquantel against cerebral coenurosis was supported by other studies too; for instance, one study was done by Afonso *et al.*, (2014) in 2014 and he has shown the response of coenurosis to the combination of fenbendazole, praziquantel and albendazole at a dose of 10 mg/kg for 3 days is effective in treating early infection of *T. multiceps* larvae in goats. The Taeniasis in the definitive host such as dog and wild calids can be treated with praziquantel, epsiprantel, mebendazole, febantel and fenbendazole (Scala and Varcasia, 2006).

Conclusion and Recommendations

Coenurosis (gids, or circling disease) is a disease of nervous system in sheep and goats, being intermediate host for the *Taenia multiceps* larval stage known as *Coenurus cerebralis*. This disease is distributed in all over the world and it is highly prevalent in Ethiopia. It causes great economic losses in sheep and goat production due to its direct effect of its high mortality and decrease in price for aesthetic purpose. Dog is the most common animal that plays great role in persistence of the life cycle of the parasite. Feeding the head of slaughtered

shoat to the dog are the most common risks associated with parasite transmission. Human can be infected if eggs are accidentally ingested as result of poor personal hygiene after being shed in the faces of the dog. The treatment of the disease in sheep and goat is not satisfactory, except surgical removal of the cyst that is not economical, so the most effective method is prevention of the disease by controlling dog contact with pasture, community awareness regarding the transmission way of the disease and the like; based on the above facts the following recommendations are forwarded:

There should be public awareness regarding the disease transmission.

Individuals who have contact with dog faeces should wash their hands with soap after work and have to keep their self-hygiene.

Society should keep their water sources and vegetable gardens out of rich of dog faeces.

Raw vegetables and fruits should be washed thoroughly before eating.

dog should be dewormed regularly.

Dog contact with pasture should be controlled.

Population of stray dog should be reduced.

Brains of the infected sheep and goats after slaughter should be disposed properly.

Back yard slaughtering or illegal butchereries should be prohibited by the law.

References

- Abo-Shehada MN, Jebreen E, Arab B, Mukbel R, Torgerson PR (2002). Prevalence of *Taenia multiceps* in sheep in northern Jordan. *Prev. Vet. Med.*, 55(3): 201-207.
- Acha PN, Szyfres B (2003). *Helminthiasis: Cestodiasis*, Text book of zoonoses and communicable diseases common to man and animals, third edition, third volume, pan Am. Health Organ., pp. 162-163.
- Achenef M, Markos T, Feseha G, Hibret A, Tembely S (1999). *Coenurus cerebralis* infection in Ethiopian highland sheep: incidence and observations on pathogenesis and clinical signs. *Trop. Anim. Health Prod.*, 31(1): 15-24.
- Adane P, Kumsa B, Hiko A, Afera B (2015). Prevalence of *Coenurus cerebralis* in Small Ruminants Slaughtered at Hashim Export Abattoir, DebreZeit, Central Oromia. *Eur. Appl. Sci.*, 7(2): 56-63.
- Afonso SM, Mukaratirwa S, Hajovska K, Capece BP, Cristofol C, Arboix M, Neves L (2011). Prevalence and morphological characteristics of *Taenia multiceps* cysts (*Coenurus cerebralis*) from abattoir-slaughtered and experimentally infected goats. *Neuroparasitol.*, 2: 1-5.
- Afonso SMS, Neves L, Pondjaa A, Macuamule C, Mukaratirwa S, Arboix M, Cristofol C, Capece BPS (2014). Efficacy of albendazole against *Taenia multiceps* larvae in experimentally infected goats. *Vet. Parasitol.*, 206(3): 304-307.
- Alemu S, Kemal J, Muktar Y, Terefe G (2015). Immunological and Molecular Diagnostic Tests for Cestodes and Metacestodes: Review. *World Appl. Sci. J.*, 33(12): 1867-1879.
- Avcioglu H, Terim KA, Yildirim A (2012). Clinical, morphological and histopathological features of bovine coenurosis: case reports. *Revue de Med. Vet.*, 163(3): 295-298.
- Balseiro A, Royo LJ, Martínez CP, de Mera IGF, Höfle Ú, Polledo L, Marín JFG (2012). Louping ill in goats, Spain, 2011. *Emerg. Infect. Dis.*, 18(6): 976.
- Bechelli k (2005). Website.parasiteproject,availableat: <http://web.stanford.edu/group/parasites/-ParaSites2010/KellyBechelli/ParasiteInfo.htm>. Accessed on March 23, 2016.
- Biswas D (2013). Ultrasound diagnosis and surgical treatment of coenurosis (GID) in bengal goat (*Capra hircus*) atchittagong metropolitan area, Chittagong, Bangladesh. *Sci. J. Vet. Adv.*, 2(5): 68-75.
- Christodouloupoulos G (2007). Two rare clinical manifestations of coenurosis in sheep. *Vet. Parasitol.*, 143(3): 368-370.
- Christodouloupoulos G, Theodoropoulos G, Petrakos G (2008). Epidemiological survey of cestode – larva disease in Greek sheep flocks. *Vet. Parasitol.*, 153(3): 368-373.
- Dejene S, Abebe B, Degefu H (2013). Study on the Major Health Problems That Causes Carcass and Organs Condemnation at Hashim's Export Abattoir, Debrezeit, Ethiopia. *Global Vet.*, 11(4): 362-371.
- Deressa A, Tilahun T, Tadesse A, Beyene M, Gebrewold G, Pal M (2012). Assessment of *Coenurus cerebralis* and its economic impact in sheep brain harvested at Ethiopian Health and Nutrition Research Institute, Ethiopia. *Int. J. Livest. Res.*, 2(2): 217-226.
- Desouky EA, Badawy AI, Refaat RA (2011). Survey on coenurosis in sheep and goats in Egypt. *Vet. Italiana.*, 47(3): 333-340.
- Dhaliwal SBB, Julal PD (2013). *Text book of parasite zoonosis*, Springer India. pp. 66-67.
- El-Din MMM (2010). The significance of subarachnoid cerebrospinal fluids (CSF) in the development of metacestode of *Coenurus cerebralis* in sheep with reference to its pathological effect. *Global Vet.*, 4(4): 343-348.
- Fentahun T, Fresebehat A (2012). Listeriosis in small ruminants: a review. *Adv. Biol. Res.*, 6(6): 202-209.
- Gadahi JA, Arshed MJ, Ali Q, Javaid SB, Shah SI (2009). Prevalence of gastrointestinal parasites of sheep and goat in and around Rawalpindi and Islamabad, Pakistan. *Vet. World.*, 2(2): 51-53.
- Ghazaei C (2007). Evaluation therapeutic effects of antihelminthic agents albendazole, fenbendazole and

- praziquantel against coenurosis in sheep. *Small Ruminant Res.*, 71(1): 48-51.
- Giadinis ND, Psychas V, Polizopoulou Z, Papadopoulos E, Papaioannou N, Kommenou AT, Thomas AL, Petridou EJ, Kritsepi-Konstantinou M, Lafi SQ, Brellou GD (2012). Acute coenurosis of dairy sheep from 11 flocks in Greece. *New Zealand Vet. J.*, 60(4): 247-253.
- Gıcik Y, Kara M, Arsalan MO (2007). Prevalence of Coenuruscerebralis in sheep in Kars Province, Turkey. *Bull. Vet. Inst. Pulawy.*, 51(3): 379-382.
- Godara R, Katoch R, Yadav A, Khajuria JK, Borkataki S (2011). Coenurosis in small ruminants: an overview. *Vet. Pract.*, 12(1): 102-105.
- Güçlü F, Uslu U, Özdemir Ö (2006). Bilateral bone perforation caused by Coenuruscerebralis in a sheep: case report. *Türkiye Parazitoloj Dergisi*, 30(4): 282-284.
- Haitchi G, Buchroithner J, Sonnenberger M, Weis S, Fellner FA (2012). Armed Forces Institute of Pathology best cases in radiologic-pathologic correlation: human coenurosis (Taenia Larva). *Radiographics.*, 32(2): 517-521.
- Haridy M, Sakai H, El-Shayma EN, Ahmed EM, Anwar S, Yanai T (2013). Coenurus cerebralis cysts in the left lateral cerebral ventricle of an ewe. *J. Vet. Med. Sci.*, 75(12): 1643.
- Hashim MA, Rashid MH, Nooruddin M (2000). Extraneural coenuriasis in Bengal goats. 4. Treatment. *Bangladesh Vet.*, 17(1): 46-49.
- Ioannidou E, Psalla D, Papadopoulos E, Diakou A, Papanikolopoulou V, Karatzias H, Polizopoulou ZS, Giadinis N (2015). Regurgitations in a Lamb with Acute Coenurosis-A Case Report. *Iranian J. Parasitol.*, 10: 301-305.
- Jawar A (2015). study on prevalence, associated factors, farmer's perception and economic importance of coenuruscerebralis in sheep and goats in and around Lega Hida district of Bale zone, DVM thesis, school of veterinary medicine, college of agriculture and veterinary medicine, Jimma university, Jimma, Ethiopia. pp. 34.
- Jibat T, Ejeta G, Asfaw Y, Wudie A (2008). Causes of abattoir condemnation in apparently healthy slaughtered sheep and goats at HELMEX abattoir, DebreZeit, Ethiopia. *Revue de Méd. Vét.*, 159(5): 305-311.
- Kheirandish R, Sami M, Azizi S, Mirzaei M (2012). Prevalence, predilection sites and pathological findings of Taeniamulticepscoenuri in slaughtered goats from south-east Iran. *Onderstepoort, J.m Vet. Res.*, 79(1): 1-5.
- Kish GF, Khodakaram-Tafti A, Hajimohammadi A, Ahmadi N (2015). Clinical and morphopathological characteristics of an enzootic occurrence of acute coenurosis (Coenurus cerebralis) in a sheep herd. *J. Parasitic Dis.*, 39(2): 280-283.
- Lescano AG, Zunt J (2013). Other cestodes: sparganosis, coenurosis and Taenia crassiceps cysticercosis. *Handbook Clin. Neurol.*, 114: 335-345.
- Mandal SS (2006). *Veterinary Parasitology at glance, first Ed.*, Int. Book Distributing Co., pp. 201-203.
- Manunta ML, Evangelisti MA, Burrai GP, Columbano N, Ligios C, Varcasia A, Scala A, Passino ES (2012). Magnetic resonance imaging of the brain and skull of sheep with cerebral coenurosis. *Am. J. Vet. Res.*, 73(12): 1913-1918.
- Miran BM (2013). coenurosis in slab-slaughtered sheep and goats in ngorongoro district: prevalence and predisposing factors of the disease, Mscthesis, adissertation submitted in partial fulfilment of the requirements for the degree of master of science in parasitology of sokoine university of agriculture. morogoro, tanzania. pp. 58.
- Miran MB, Nzalawahe J, Kassuku AA, Swai ES (2015). Prevalence of coenurosis in sheep and goats at three slaughter slabs in Ngorongoro District, Tanzania, *Trop. Anim. Health Prod.*, 47(8): 1591-1597.
- Moazami G (2005). Diseases Caused by Helminthic, Text book of Walsh and Hoyt's Clin. Neuroophthalmology., 3: 2853-2877.
- Neni S (2012). Study on the prevalence and economic implication of coenurus cerbrallis in sheep and goat in and around Yabello district of Borena zone, DVM thesis, college of Agriculture and veterinary Medicine, Jimma university, Jimma, Ethiopia. pp. 31.
- Nourani H, Pirali Kheirabadi K (2009). Cerebral coenurosis in a goat: Pathological findings and literature review. *Comp. Clin. Pathol.*, 18(1): 85-87.
- Oge H, Oge S, Gonenc B, Ozbakis G, Asti C (2012). Coenurosis in the lumbar region of a goat: a case report. *Vet. Med.*, 57(6): 308-13.
- Oryan A, Akbari M, Moazeni M, Amrabadi OR (2014). Review Paper Cerebral and non-cerebralcoenurosis in small ruminants. *Trop. Biomed.*, 31(1): 1-16.
- Oryan A, Goorgipour S, Moazeni M, Shirian S (2012). Abattoir prevalence, organ distribution, public health and economic importance of major metacestodes in sheep, goats and cattle in Fars, southern Iran. *Trop. Biomed.*, 29(3): 349-359.
- Oryan A, Moazeni M, Amrabadi O, Akbari M, Sharifiyazdi H (2015). Comparison of distribution pattern, pathogenesis and molecular characteristics of larval stages of Taeniamulticeps in sheep and goats. *Small Ruminant Res.*, 132: 44-49.
- Özkan C, Yildirim S, Kaya A (2011). Clinical coenurosis (Coenuruscerebralis) and associated pathological findings in a calf, *Pak. Vet. J.*, 31(3): 263-266.
- Rosen S, Savinetsky A, Kisseleva N, Khassanov B, Pereladov A (2005). Dung in the Desert: Preliminary Results of the Negev Holocene Ecology Project1. *Curr. Anthropol.*, 46(2): 317-326.
- Rostami S, Beech RN, Salavati R, Baneshi MR, Kamyabi H, Harandi MF (2013). Morphometric analysis of larval rostellar hooks in Taeniamulticeps of sheep in Iran and its association with mitochondrial gene variability. *Iranian J. Parasitol.*, 8(4): 579.
- Roy ME, Wrigley RH, Kraft SL, Steyn P, Zekas LJ, Park RD, Withrow SJ (2007). Of the international veterinary radiology association and the American college of

- veterinary radiology. *Vet. Radiol. Ultrasound.*, 48(2): 163-188.
- Sabbatani S, Zucchelli M, Calbucci F, Roncaroli F, Chiodo F (2004). A case of cerebral coenurosis, *Le infezioni in medicina: rivista periodica di eziologia, epidemiologia, diagnostica, clinica e terapia delle patologie infettive*, 12(3): 205-210.
- Scala A, Cancedda GM, Varcasia A, Ligios C, Garippa G, Genchi C (2007). A survey of *Taenia multiceps* coenurosis in Sardinian sheep. *Vet. Parasitol.*, 143(3): 294-298.
- Scala A, Varcasia A (2006). Updates on morphobiology, epidemiology and molecular characterization of coenurosis in sheep. *Parassitologia.*, 48(1-2): 61-63.
- Schuster RK, Sivakumar S, Wieckowsky T (2010). Non-cerebral coenurosis in goats. *Parasitol. Res.*, 107(3): 721-726.
- Scott PR (2012). Diagnosis and treatment of coenurosis in sheep, University of Edinburgh, Easter Bush Veterinary Centre, Roslin, Midlothian, Scotland, United Kingdom. *Vet. Parasitol.*, 189(1): 75-78.
- Sharma DK, Chauhan PPS (2006). Coenurosis status in Afro-Asian region: a review. *Small Ruminant Res.*, 64(3): 197-202.
- Tavassoli M, Malekifard F, Soleimanzadeh A, Tajik H (2011). Prevalence of *Coenurus cerebralis* in sheep in Northwest of Iran. *Vet. Res. Forum*, 2(4): 274-276.
- Upadhayay AK (2005). Text book of preventive medicine, first edition, Int. book distributing company (Publ. Div.), pp. 452-454.
- Uslu U, Guclu F (2007). Prevalence of *Coenurus cerebralis* in sheep in Turkey. *Med. Weterynarina.*, 63(6): 678-680.
- Varcasia A, Jia WZ, Yan HD, Manunta ML, Pipia AP, Garippa G, Schuster RK (2012). Molecular characterization of subcutaneous and muscular coenurosis of goats in United Arab Emirates. *Vet. Parasitol.*, 190(3): 604-607.
- Varcasia A, Tosciri G, Coccone GNS, Pipia AP, Garippa G, Scala A, Damien V, Vural G, Gauci CG, Lightowlers MW (2009). Preliminary field trial of a vaccine against coenurosis caused by *Taenia multiceps*. *Vet. Pathol.*, 162(3): 285-289.